

The effect of tooth position on the image of unerupted canines on panoramic radiographs

V. Gavel and L. Dermaut

Department of Orthodontics, University of Gent, Belgium

SUMMARY The purpose of this study was to evaluate whether panoramic tomograms, which are routinely used in orthodontic practice, can provide adequate information to localize an impacted canine. The effect of changes in position and inclination of an impacted canine on orthopantomograms was investigated in an experimental set-up. An upper canine was removed from a human skull and replaced in a positioning system, enabling simulated positional variations in impactions.

In comparison with the image of a contralateral well-aligned canine, the length of the impacted tooth always decreased or remained unchanged, whereas the tooth width increased or remained unchanged. The angulation of the image was unaffected by varying the position of the impacted canine, but altered when the inclination of the tooth in a sagittal or frontal direction was changed. If there was any transversal shift of the impacted canine on the orthopantomogram, it was always towards the mid-sagittal plane. The curvature of the tooth increased after dorsal inclination and decreased after ventral inclination (in comparison with the contralateral well-aligned canine).

Introduction

Impaction of maxillary canines has a reported incidence of between 0.92 (Dachi and Howell, 1961) and 1–2 per cent (Rayne, 1969; Thilander and Jacobsson, 1968; Brin *et al.*, 1986). Four important aetiological factors are reported in the literature to explain impaction: obstruction due to environmental disturbances (Dewel, 1949; Hitchin, 1956), ectopic position of the tooth germ, lack of adequate guidance along the roots of the lateral incisors (Miller, 1963/4; Becker *et al.*, 1981; Becker, 1984), and general systemic diseases (Bass, 1967).

In orthodontic treatment planning, the exact localization of the position of an impacted canine is necessary, since the decision whether the canine should be extracted or retained may considerably influence the treatment plan. Limited intervention (Leivesley, 1984), such as extraction of the deciduous canine, or tunnelling of the canine with or without orthodontic guidance, can only be performed after careful estimation of the tooth's

position. Moreover, accurate knowledge of the position of the impacted canine may contribute to a less invasive surgical procedure if exposure of the canine is required. A peri-apical repositioning flap procedure might be the choice in buccally-retained canines, whereas extensive removal of bone might be necessary in the case of palatal impaction.

According to the literature, impaction of the canines occurs more frequently on the palatal than buccal side of the arch. Hitchin (1956), Rayne (1969), Ericson and Kurol (1987), and Jacoby (1983) found palatal impaction in approximately 85 per cent of cases. Gaulis and Joho (1978) reported palatal impaction in 66 per cent and Fournier *et al.* (1982) in 75 per cent of subjects referred. Nordenram and Strömberg (1966) investigated 500 impacted canines and found that in 50 per cent of the cases the canine was palatally placed. This variation in percentages might be due to a difference in interpretation of the defined position, as well as to biological variation.

Clinical investigation is of the utmost importance in the diagnosis of impacted canines. The eruption of the contralateral canine, the inclination of the lateral incisors, and the evaluation of peg-shaped or missing incisors has to be visually evaluated. Palpation of the bulbus buccally and mobility of the deciduous maxillary canine may indicate satisfactory eruption of the canine. However, this must be confirmed by radiographic techniques (Pateroo and Kiminki, 1962).

Many radiographic registrations are used to diagnose impaction, which are based on two main principles:

1. The cone-shift or parallax technique, which aims to register the relative displacement of an object in relation to the environment.
2. The degree of magnification of the imaged object, in comparison with the surrounding teeth, may also give an indication of the malposition of the impacted tooth.

Both principles enable the localization of displaced teeth on radiographic films. Computerized tomography and magnetic resonance imaging are important aids for imaging impacted teeth, but are still too expensive to be used on a routine basis.

The purpose of this study was to evaluate the information stored on routine orthopantomograms and cephalograms in an orthodontic practice, in an attempt to localize the impacted canine. In this study, the effect of changes in position and inclination of impacted canines on orthopantomograms was investigated.

Materials and methods

The material for this experimental study consisted of a series of dental panoramic tomograms taken with a Cranex DC II pantomograph (Soredex, Helsinki, Finland). A dry skull with well-aligned teeth was positioned in the pantomograph using a removable jig, which enabled reproducible repositioning (Figure 1). The teeth were then removed from the skull and transferred to an acrylic palatal device, which was made on the skull and enabled maintenance of the position of all the teeth in their original positions

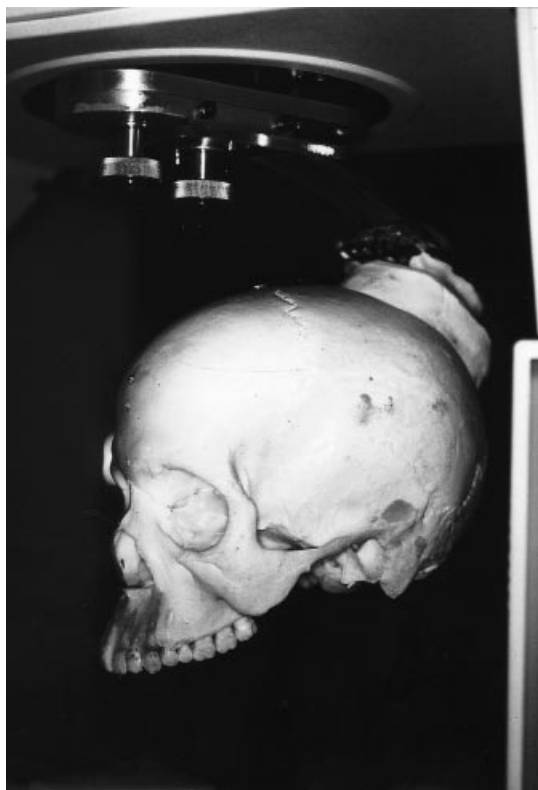

Figure 1 System for ensuring reproducibility of positioning of the skull.

(Figure 2). Since it was the purpose of this investigation to compare the tooth dimensions of the impacted canine with the contralateral one, a panoramic radiograph of the full dentition was taken. The canine was then removed from the acrylic model and fixed to a positioning system, which enabled changes in position and inclination in a standardized way within well defined biological and realistic limits (Figure 3). Metallic markers were used to allow superimposition of the different orthopantomograms enabling standardized measuring (Figure 4).

The positioning system for the isolated canine was reproducible and enabled the exact position of the canine to be described (Figure 5). The whole procedure was followed to avoid obstacles in the skull when varying the position of the canine for the different exposures.

All positional variations (Figure 6) could be meticulously registered three-dimensionally in

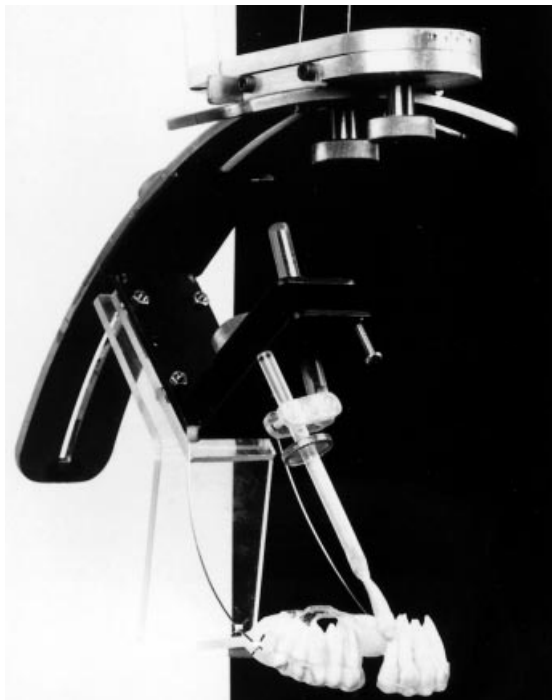

Figure 2 An acrylic palatal device maintaining the original position of all teeth.

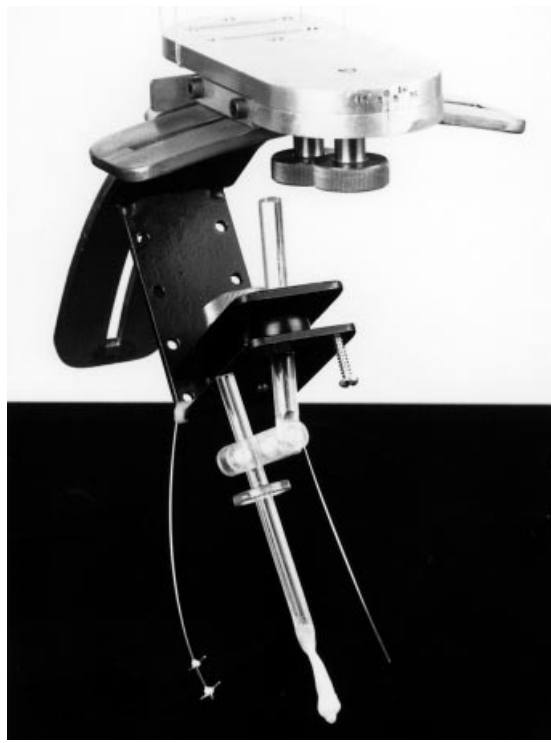

Figure 3 System to fix the isolated canine to the orthopantomograph.

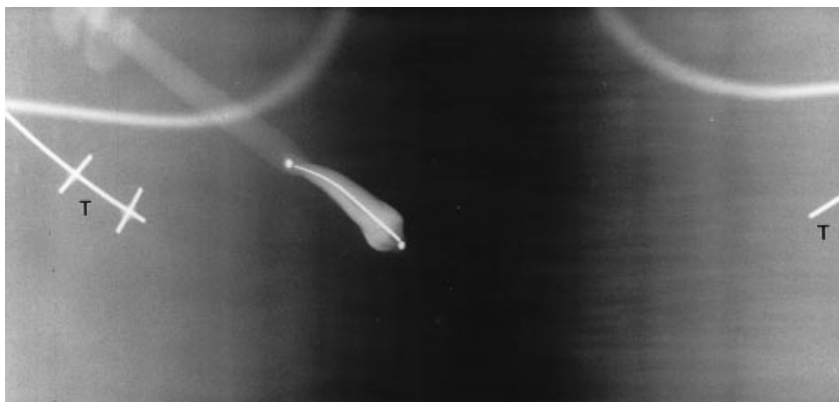

Figure 4 Orthopantomographic imaging of the isolated canine. Metallic tentacles were used for superimposition of the different orthopantomograms.

the system. To test the reliability, six different parameters were measured twice in 10 different positions. The percentage error in repeated measurements was less than 6 per cent. These

parameters and measuring techniques are illustrated in Figure 7.

The positioning system of the 13 was isolated and separate panoramic radiographs of this tooth

in different positions were taken (Figure 4). All measurements were made twice with callipers in a darkened room.




Figure 5 Positioning system for the isolated canine.

The isolated canine was first located in a buccally impacted position. The position of the crown was defined as the most anterior position in the sagittal plane at a vertical level situated close to the middle of the root of the lateral incisor. The variations in position are illustrated in Figure 6. Starting from the buccally impacted position, three different displacements were simulated: 10 mm towards the mid-sagittal plane; 10 mm posteriorly in the sagittal plane; and 5 mm in a vertical direction. In each position, different changes in inclination were registered. In a sagittal direction, the three inclinations varied between 30 and 70 degrees, whereas frontal tilting varied between 60 and 100 degrees. All positional changes were illustrated in a series of diagrams, with each series representing the different changes for each parameter. Figure 8A–F, shows a compilation of an example of each series of diagrams. A comparison with the well-aligned contralateral canine was made using this tooth.

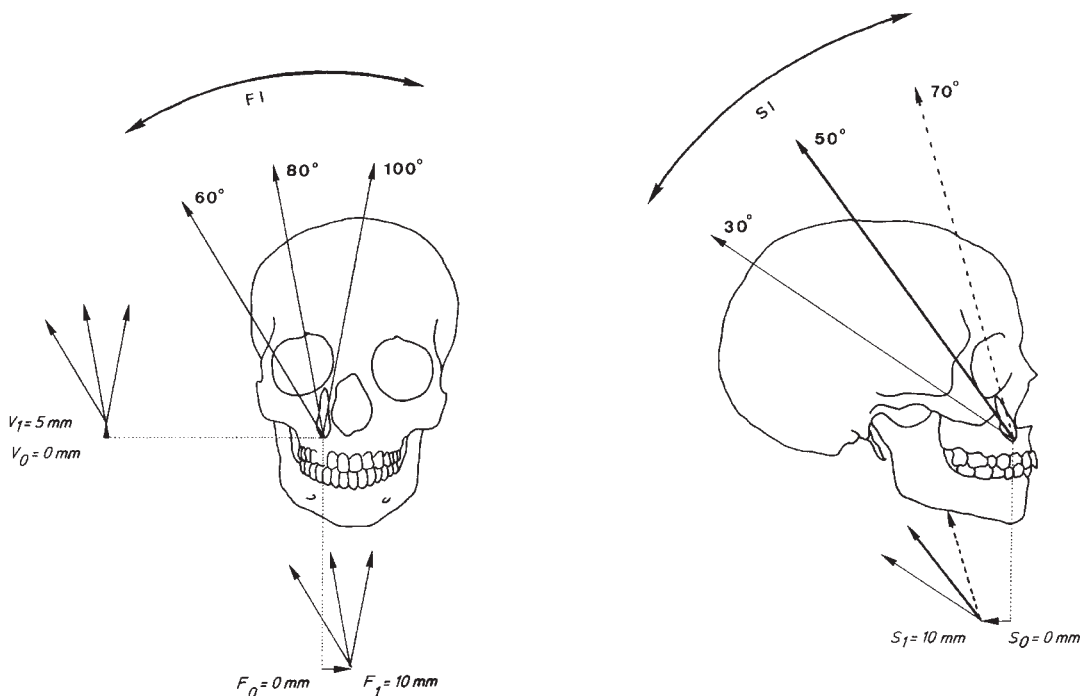


Figure 6 Different studied combinations of displacements and inclinations. S_0 = buccally impacted position in the sagittal plane; S_1 = posterior displacement (10 mm) in the sagittal plane; F_0 = buccally impacted position in the frontal plane; F_1 = displacement towards the mid-sagittal plane (10 mm); V_0 – V_1 = vertical displacement (0–5 mm); FI = inclinations in the frontal plane (60–100 degrees); SI = inclinations in the sagittal plane (30–70 degrees).

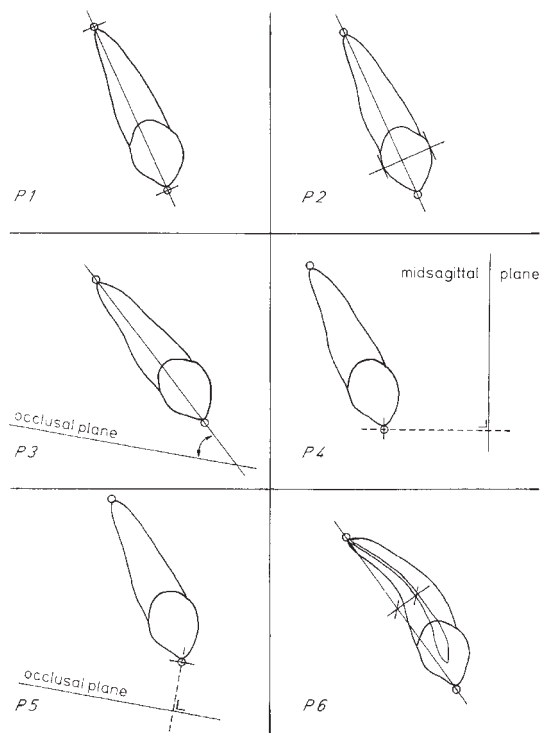


Figure 7 Illustration of the different parameters: P1 = tooth length; P2 = crown width; P3 = angulation related to the occlusal plane; P4 = lateral shift related to the mid-sagittal plane; P5 = vertical level related to the occlusal plane; P6 = amount of curvature due to distortion.

Results

Changes in apparent tooth length

In the buccally impacted position (Figures 8A and 9), the average tooth length was less than the length of the contralateral well-aligned canine. Tilting in the sagittal plane shortened the tooth, while uprighting resulted in lengthening. As the tooth was uprighted in the frontal plane, the degree of tilting in the sagittal plane was more pronounced. The more the canine was tilted laterally in the frontal plane, the less the tooth length was affected by tilting in the sagittal plane. Vertical displacement of 5 mm from this position produced similar results. Although, in the case of posterior displacement and displacement towards the mid-sagittal plane, the diagrams were of a similar construction, the average length

of the impacted canine was similar to the length of the contralateral canine. In a posteriorly displaced position, the sagittal inclination showed variations in apparent tooth length in cases of extreme tilting and uprighting in the frontal plane.

Changes in apparent tooth width

In the buccally impacted position (Figures 8B and 9), after vertical displacement, the average tooth width was the same in relation to the width of the contralateral well-aligned canine. Only inclination in the sagittal plane widened the crown slightly. Posterior displacement clearly widened the crown and this widening was at its maximum when the tooth was uprighted in the frontal plane. After displacement towards the mid-sagittal plane, the crown width showed a pattern similar to the buccal position. The widening of the tooth crown, caused by inclinations in the sagittal direction, was emphasized.

Tooth angulation

In all the simulated impactions, the average value of the angle between the tooth axis and the occlusal plane was lower than the value of the contralateral well-aligned canine (Figures 8C and 9). The lowering of the value of the angle was mainly caused by changing the inclination of the impacted canine. All diagrams showed a decrease of this angle as the tooth was more inclined in a sagittal direction. Uprighting in the frontal plane resulted in a constant increase of this angle. This clear tendency should be related to the displaced position towards the mid-sagittal plane. In the most uprighted position in the frontal plane, the inclination in a sagittal direction had no further impact on the tooth angulation, which remained, in all cases, at 90 degrees.

Lateral shift

The crown point of the canine tended to move towards the mid-sagittal plane when this tooth was impacted buccally (Figures 8D and 9) or when it was vertically displaced from this position. This also occurred after displacement of the canine

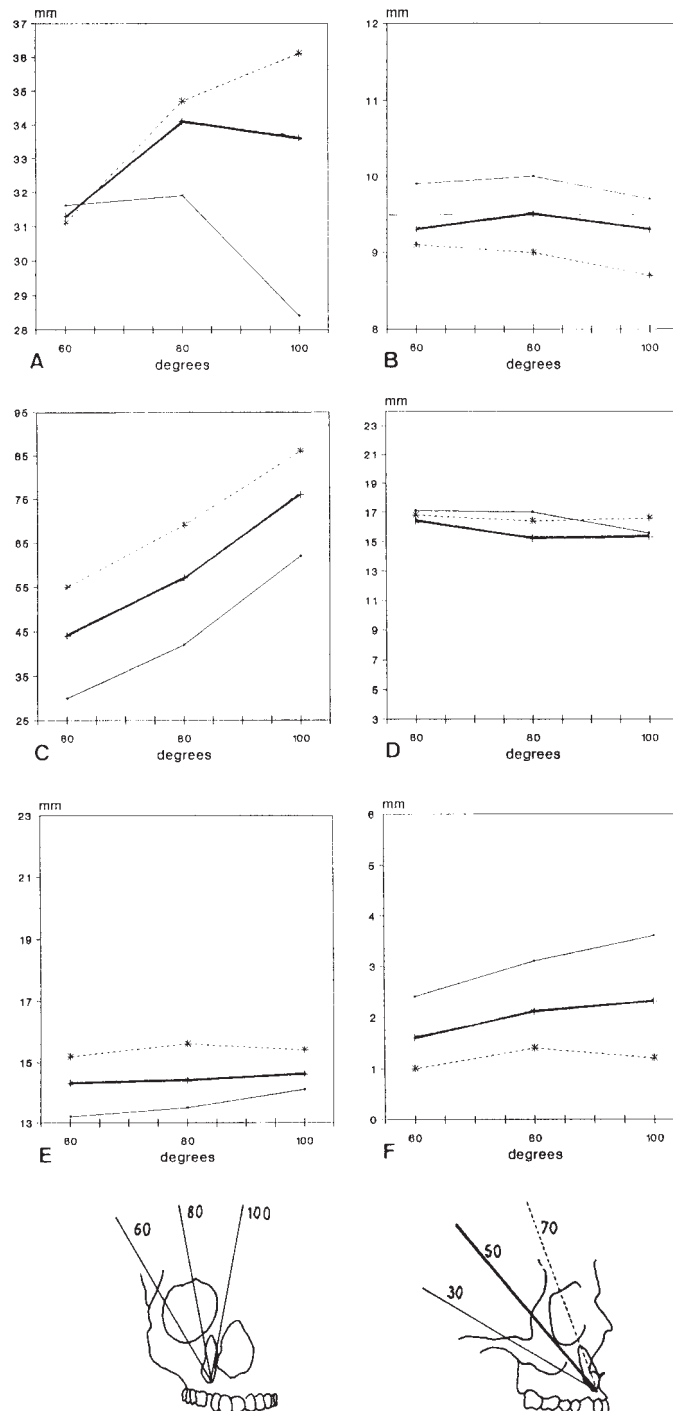


Figure 8 Examples of diagrams of investigated parameters on orthopantomograms related to changes in inclination in the frontal plane (x-axis) for three different inclinations in the sagittal plane (thin, thick, and dashed lines) in the buccally impacted tooth. Investigation parameters (y-axis): (A) tooth length; (B) tooth width; (C) tooth angulation; (D) lateral shift to the medial plane; (E) vertical distance; and (F) curvature.


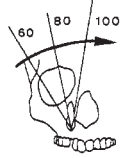
POSITIONS / INCLINATIONS	BUCCAL POSITION	POSTERIOR DISPLACEMENT	DISPLACEMENT TOWARDS MIDSAGITTAL PLANE	SAGITTAL INCLINATION	FRONTAL INCLINATION
PARAMETERS					
APPARENT TOOTH LENGTH	↓	=	=	↓	*
APPARENT TOOTH WIDTH	=	↑	=	↑	×
ANGULATION TOOTHAXIS / OCCL. PLANE	×	×	×	↓	↑
LATERAL SHIFT TOWARDS MS PLANE	↓	↑	↓	×	×
VERTICAL DIST.	=	↑	↑	×	×
CURVATURE	×	×	×	↑	×

Figure 9 Inter-relationship between parameters. =, comparable to the value of the contralateral canine; ↓, decrease in comparison with the contralateral canine; ↑, increase in comparison with the contralateral canine; ×, no influence in comparison with the contralateral canine; *, the more the uprighing in the frontal plane the more pronounced the impact of the sagittal inclination on tooth length.

towards the mid-sagittal plane. However, after posteriorly displacing the tooth, the crown point tended to move away from the mid-sagittal plane: the distance between the crown point and the mid-sagittal plane corresponded to the distance measured with the contralaterally well-aligned canine. The changes in inclination did not show differences with the parameter measured.

Vertical distance to the occlusal plane

In these diagrams (Figures 8E and 9), it was not necessary to take into account the value of the contralaterally aligned canine, since this distance was equal to zero.

Comparison of the impacted positions demonstrated that posterior displacement and displacement of the canine towards the mid-sagittal plane projected the crown point somewhat higher on the orthopantomogram. Therefore, vertical

displacement of the canine can lead to a higher projection of the crown point.

Curvature

As shown in Figures 8F and 9, the average curvature value corresponded to that of the contralaterally aligned tooth. However, in the case of sagittal inclination, the curvature increased independently of the impacted position. With displacement towards the mid-sagittal plane, the effect of sagittal tipping was more extreme. Sagittal inclination did not result in further alterations in this position when the tooth was fully uprighing in the frontal plane.

Discussion

Several studies have been undertaken to describe the principles of image formation or deformation

on orthopantomographs, using either a mathematical approach (Tronje *et al.*, 1981) or experimental set-ups with geometric objects (Samawi and Burke, 1984; Philipp and Hurst, 1978). In two clinical studies, Fox (1995), and Ericson and Kurol (1987) investigated the validity of the orthopantomogram in localizing impacted maxillary canines. They concluded, mainly based on the magnification of the crown size, that localization of the impacted canines could be predicted in approximately 80 per cent of cases. The purpose of this study was to evaluate the possible contributing effect of other parameters, in addition to magnification of crown size, in an attempt to determine more reliably the position of the impacted canine. This study forms part of an extended research programme including cephalometric radiography.

The free set-up of the experiment made it possible to register the behaviour of an impacted canine (anatomical object) on a pantomographic image without the restriction of environmental factors, such as bony structures and tooth roots. This set-up also requires that the conclusions from this experiment be interpreted correctly before they are transferred to a clinical situation.

The pantomographic equipment used was a Cranex type. If another machine is used, the magnification factor would have to be adjusted (as mentioned in the manual). Nevertheless, the principle of image formation and the comparison with the contralateral canine remains the same.

Using this set-up, perfect positioning of the teeth in the pantomographic equipment could be achieved. This was necessary for a correct interpretation of the displacements and inclinations.

In this study, a comparison was made between an impacted canine and a well-aligned erupted contralateral canine, which implies a unilateral impaction. Bilateral impaction only occurs in a small minority of cases (16 per cent, Wolf and Mattila, 1979; 20 per cent, Mossey *et al.*, 1994). However, even in the case of bilateral impaction, the principles affecting changes in 'size' and 'inclination' remain valid.

The rotation of the canine around its own axis was left unchanged (30 degrees), based on the clinical impression that a buccally impacted canine is almost never rotated and that the

palatally impacted canine rotates towards the median plane. This knowledge may provide extra information to localize an impacted canine. The image sharpness of the projected object was not taken into account. Blurring of the image corresponds to the projection of a tooth that is outside the image plane. As for the interpretation of the buccal and palatal impaction, the magnification in a case of blurring will still be a clear parameter. However, the interpretation of imaging of objects that are not sharp outside of the image plane still remains unreliable. In these cases, clinical localization is, in general, very obvious.

The results of this experimental study show that many phenomena are familiar because they are based on the mechanism of magnification, one of the principles of radiography. Tooth length and crown width are values principally affected by this magnifying factor, which is determined by the tooth-film distance. Distortions and lack of sharpness are created by the imaging of a tooth outside the image plane and the specific image creation of the orthopantomogram.

Tooth inclinations, both in the sagittal and in the frontal plane, also influence the above-mentioned values. A compilation of the findings from this are illustrated in Figure 9.

Conclusions

The following statements can help to define the exact location of impaction of a maxillary canine in clinical situations:

1. Although buccal impaction shortens the tooth length on orthopantomographs, this is mostly caused by its inclination in a sagittal direction. The more the tooth is uprighted in the frontal plane, the more pronounced the influence of the sagittal inclination on tooth length.
2. Displacing the impacted tooth in a posterior direction (i.e. palatal impaction) widens the crown width. Inclination in a sagittal direction and uprighting towards the mid-sagittal plane enhances this phenomenon.
3. The impacted position (buccal or palatal) of the impacted canine does not influence angulation tooth-axis/occlusal plane. This value changes negatively when the tooth is inclined

in a sagittal direction and positively when the tooth is uprighted in the frontal plane.

4. Buccal and median impaction (in the frontal plane) shorten the imaged distance to the mid-sagittal plane compared with imaging of the well-aligned canine. Displacement in a sagittal direction (i.e. palatal impaction) widens this distance. However, in most clinical situations when the canine is palatally impacted, the crown most often migrates towards the mid-sagittal plane resulting in a shortening of this distance on the orthopantomogram.
5. The migration of the impacted canine in a sagittal or median direction projects the crown point higher on the orthopantomogram than a canine buccally impacted at the same vertical level.
6. An increased curvature of the root of an impacted canine demonstrates an inclination of the tooth in a sagittal direction.

The experimental set-up used in this investigation made it possible to objectively picture the behaviour of the variable location of an impacted canine on an image display. Future research involving cephalograms may provide extra information that could lead to a better interpretation of an exact location. Therefore, the present findings will be combined with an evaluation of the cephalographic registration in a second study.

Address for correspondence

Professor L. Dermout
Department of Orthodontics
School of Dentistry
University of Gent
UZ – De Pintelaan 185
B-9000 Gent
Belgium

Acknowledgements

The authors wish to thank Mr G. Dermout for the drawings and photographs, and Mrs B. Jouret for typing the manuscript.

References

- Bass T B 1967 Observations of the misplaced upper canine tooth. *Dental Practitioner* 18: 25–33
- Becker A 1984 Etiology of maxillary canine impactions (Letter to the Editor). *American Journal of Orthodontics* 86: 437–438
- Becker A, Smith P, Behar R 1981 The incidence of anomalous maxillary lateral incisors in relation to palatally-displaced canines. *Angle Orthodontist* 51: 24–29
- Brin I, Becker A, Shalhav M 1986 Position of the maxillary permanent canine in relation to anomalous or missing lateral incisors: a population study. *European Journal of Orthodontics* 8: 12–16
- Dachi S F, Howel F V 1961 A study of impacted teeth. *Oral Surgery* 14: 1165–1169
- Dewel B F 1949 The upper cuspid: its development and impaction. *Angle Orthodontist* 19: 79–90
- Ericson S, Kurol J 1987 Radiographic examination of ectopically erupting maxillary canines. *American Journal of Orthodontics and Dentofacial Orthopedics* 91: 483–492
- Fournier A, Turcotte J Y, Bernard C 1982 Orthodontic considerations in the treatment of maxillary impacted canines. *American Journal of Orthodontics* 81: 236–239
- Fox N A 1995 Localising maxillary canines using dental panoramic tomography. *British Dental Journal* 179: 416–420
- Gaulis R, Joho J-P 1978 Parodonte marginal de canines supérieures incluses: évaluation suite à différentes méthodes d'accès chirurgical et de système orthodontique. *Schweizerische Monatsschrift für Zahnheilkunde* 6: 1249–1259
- Hitchin A D 1956 The impacted maxillary canine. *British Dental Journal* 100: 1–14
- Howard R D 1972 The displaced maxillary canine: positional variations associated with incisor resorption. *Dental Practitioner* 22: 279–287
- Jacoby H 1983 The etiology of maxillary canine impactions. *American Journal of Orthodontics* 84: 125–132
- Leivesley M 1984 Minimizing the problem of impacted and ectopic canines. *Journal of Dentistry for Children* 51: 367–370
- Miller B H 1963/4 Influence of congenitally missing teeth on the eruption of the upper canine. *Transactions of the British Society for the Study of Orthodontics*, pp. 17–24
- Mossey P A, Campbell H M, Luffingham J K 1994 The palatal canine and the adjacent lateral incisor: a study of the west of Scotland population. *British Journal of Orthodontics* 21: 169–174
- Nordenram A, Strömberg C 1966 Positional variations of the impacted upper canine. *Oral Surgery* 22: 711–714
- Pateroo Y V, Kiminki A 1962 Further study of the palato-labial position of retained upper canines. *Finska Tandläkarnas Förhandlingar* 58: 274–300

- Philipp R G, Hurst R V V 1978 The cant of the occlusal plane and distortion in the panoramic radiograph. *Angle Orthodontist* 48: 317–323
- Rayne J 1969 The unerupted maxillary canine. *Dental Practitioner* 19: 194–203
- Rohrer A 1929 Displaced and impacted canines. *International Journal of Orthodontics* 15: 1002–1020
- Samawi S S B, Burke P H 1984 Distortion in the orthopantomogram. *British Journal of Orthodontics* 11: 100–107
- Thilander B, Jacobsson S O 1968 Local factors in impaction of maxillary canines. *Acta Odontologica Scandinavica* 26: 145–168
- Tronje G, Welander U, McDavid W D, Morris C R 1981 Image distortion in rotational panoramic radiography. *Acta Radiologica Diagnosis* 22: 689–698
- Wolf J E, Mattila K 1979 Localization of impacted maxillary canines by panoramic tomography. *Dento Maxillo-Facial Radiology* 8: 85–91